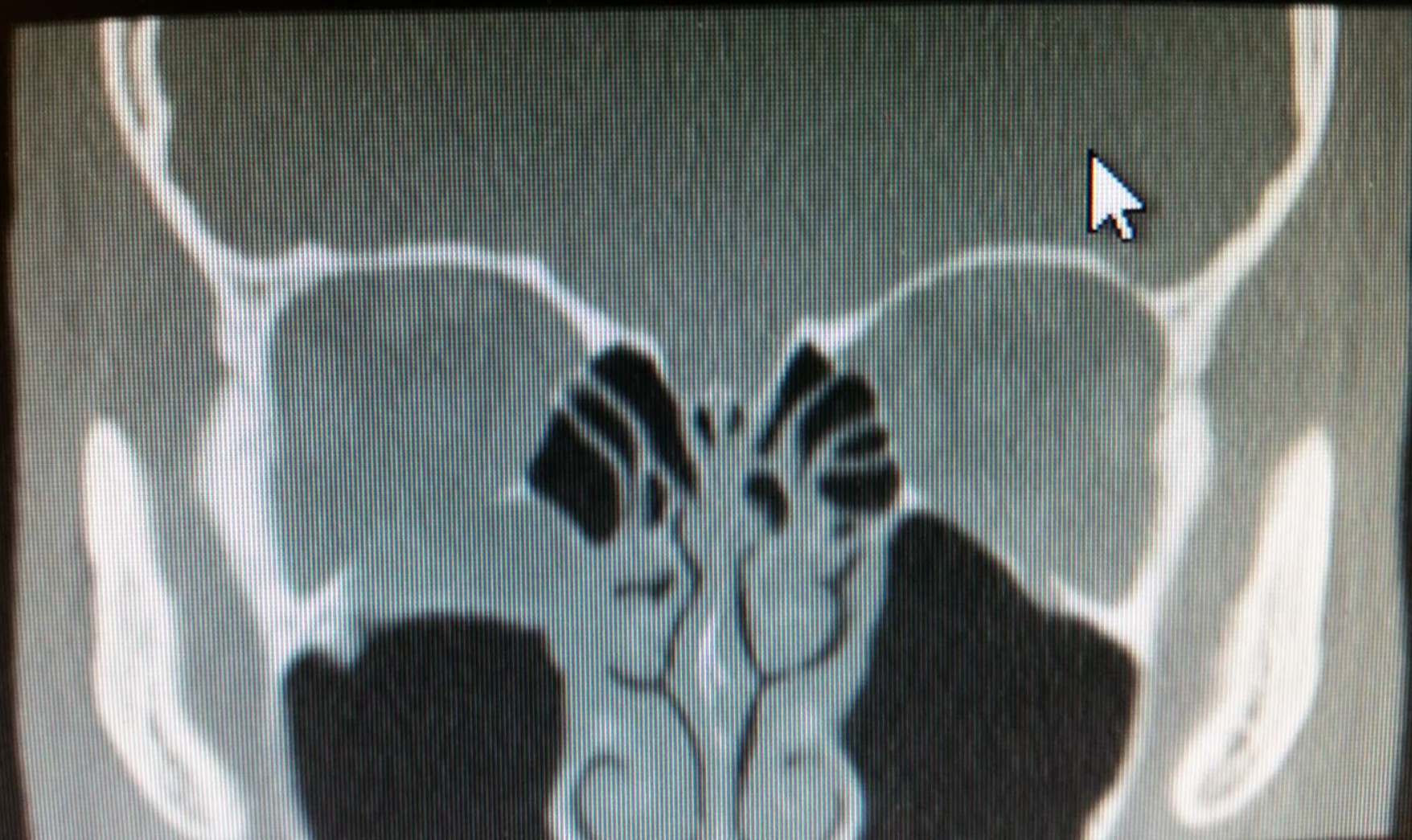
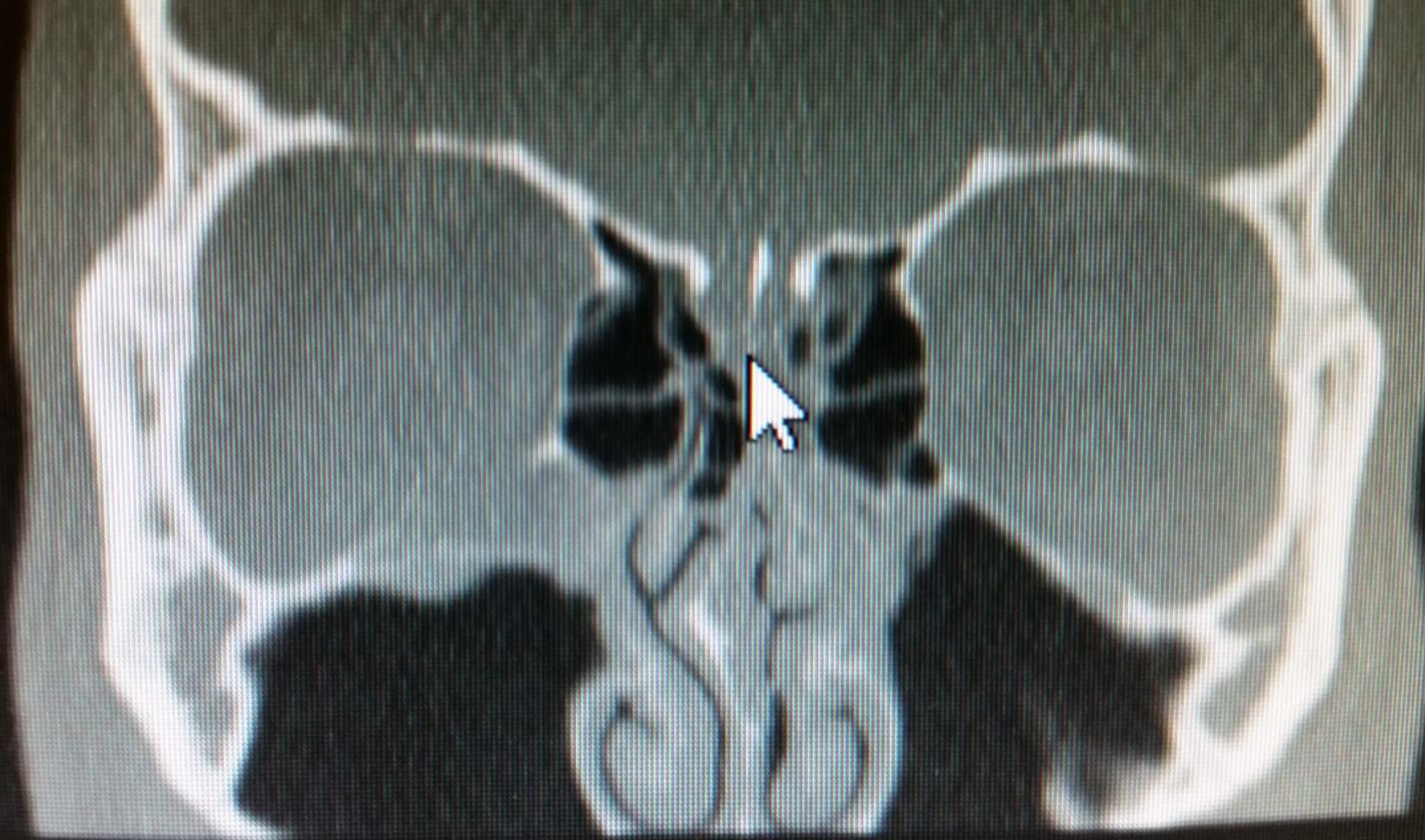
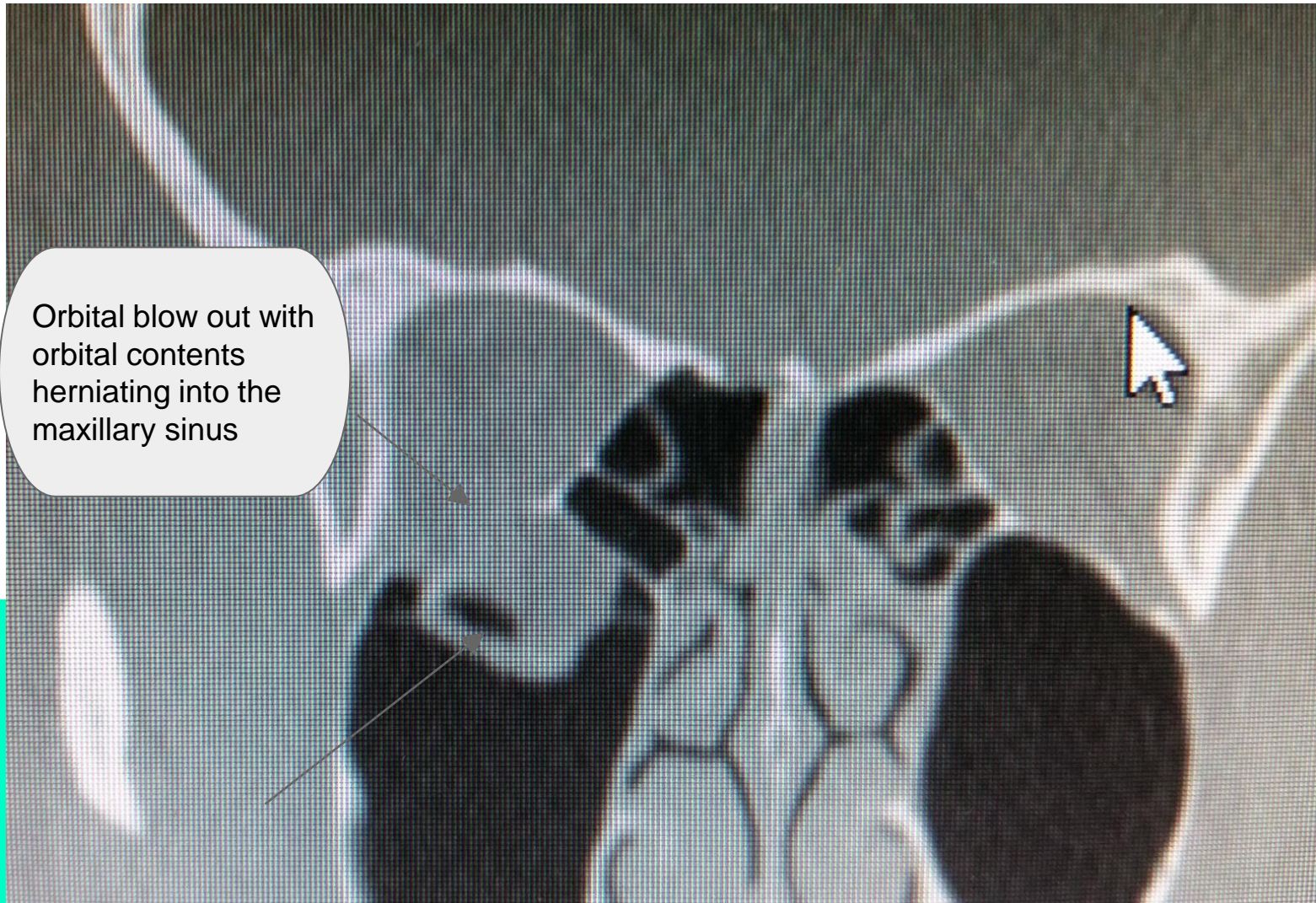
RIGHT ORBITAL FLOOR FRACTURE

Dr. Bryan McLelland, DDS

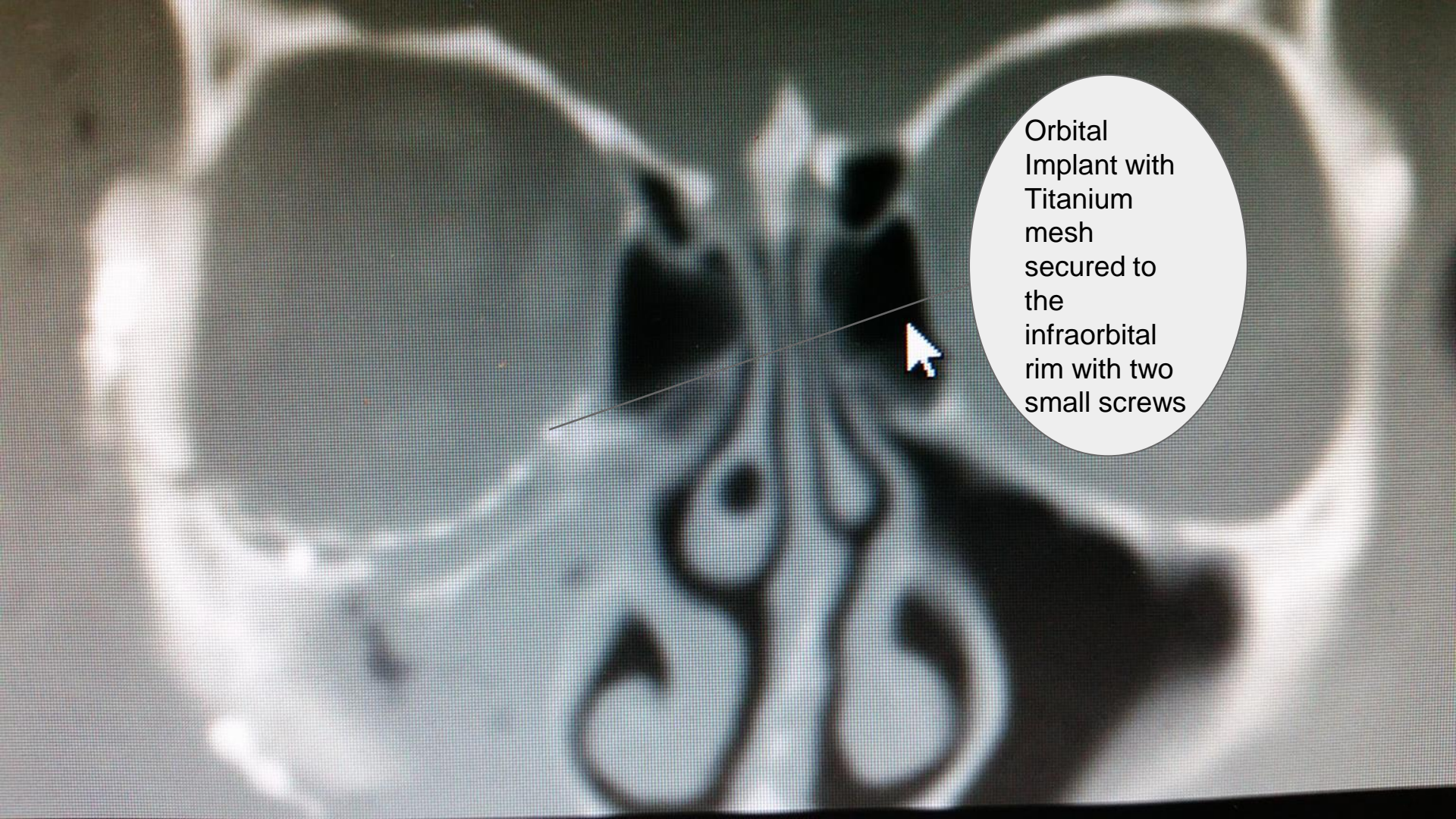





Orbital blow out with
orbital contents
herniating into the
maxillary sinus







Orbital
Implant with
Titanium
mesh
secured to
the
infraorbital
rim with two
small screws



Titanium mesh
impregnated
porous
polyethylene
implant

WWW.DENTISTBRAIN CANDY.COM

STORE.DENTISTBRAIN CANDY.COM