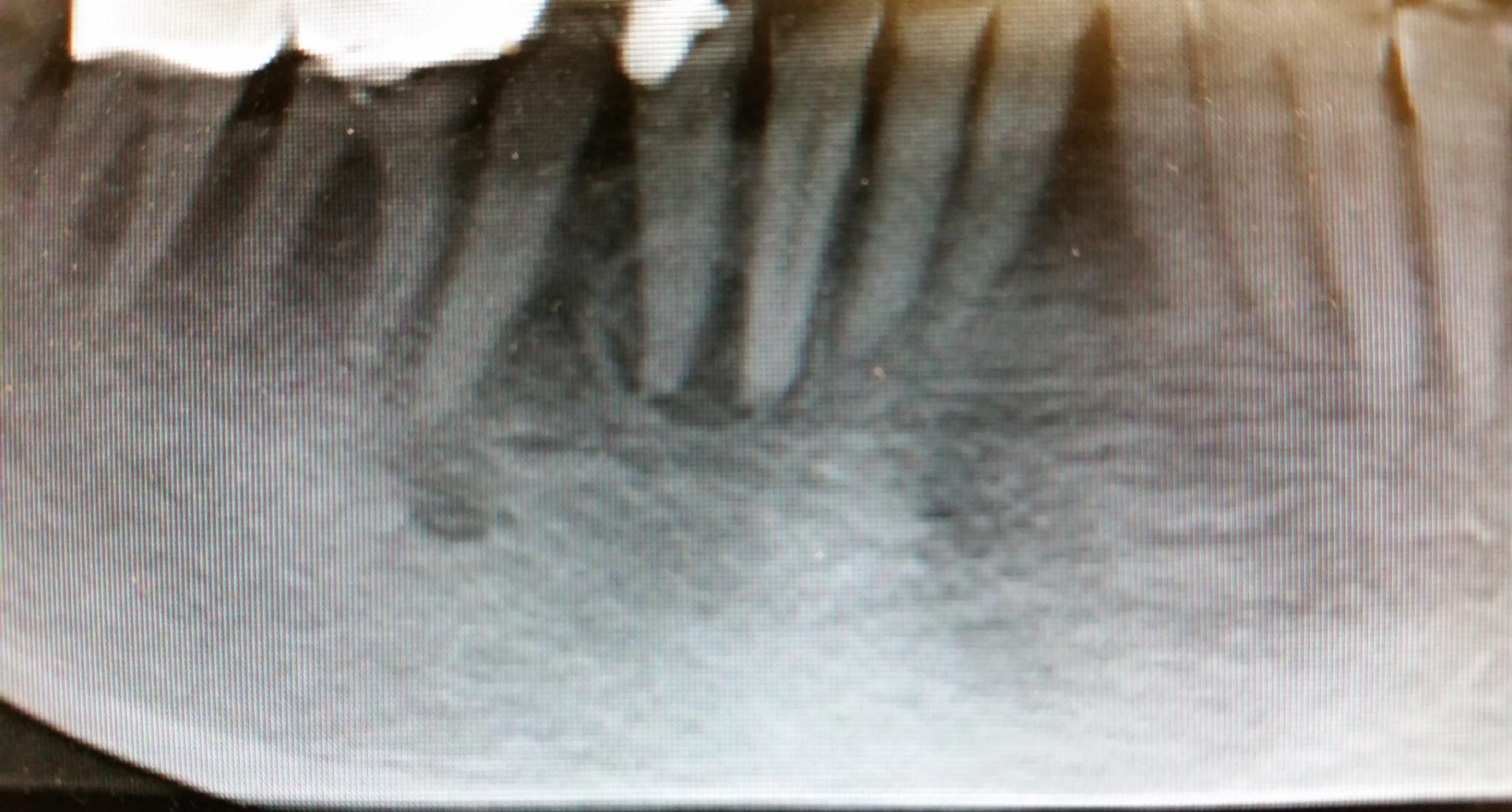
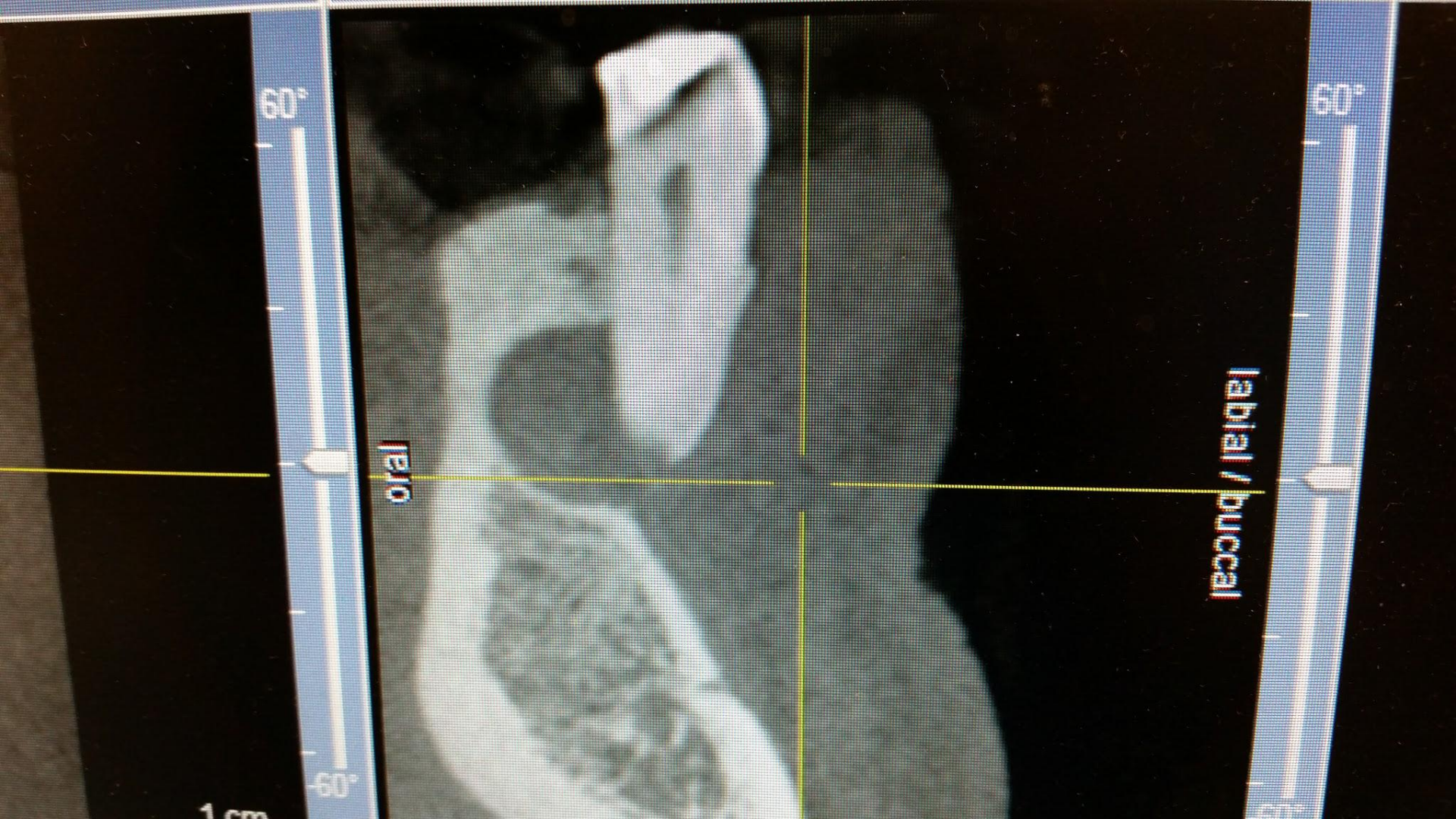
Recurrent OKT

Dr. Bryan W. McLelland, DDS
www.dentistbraincandy.com







60°

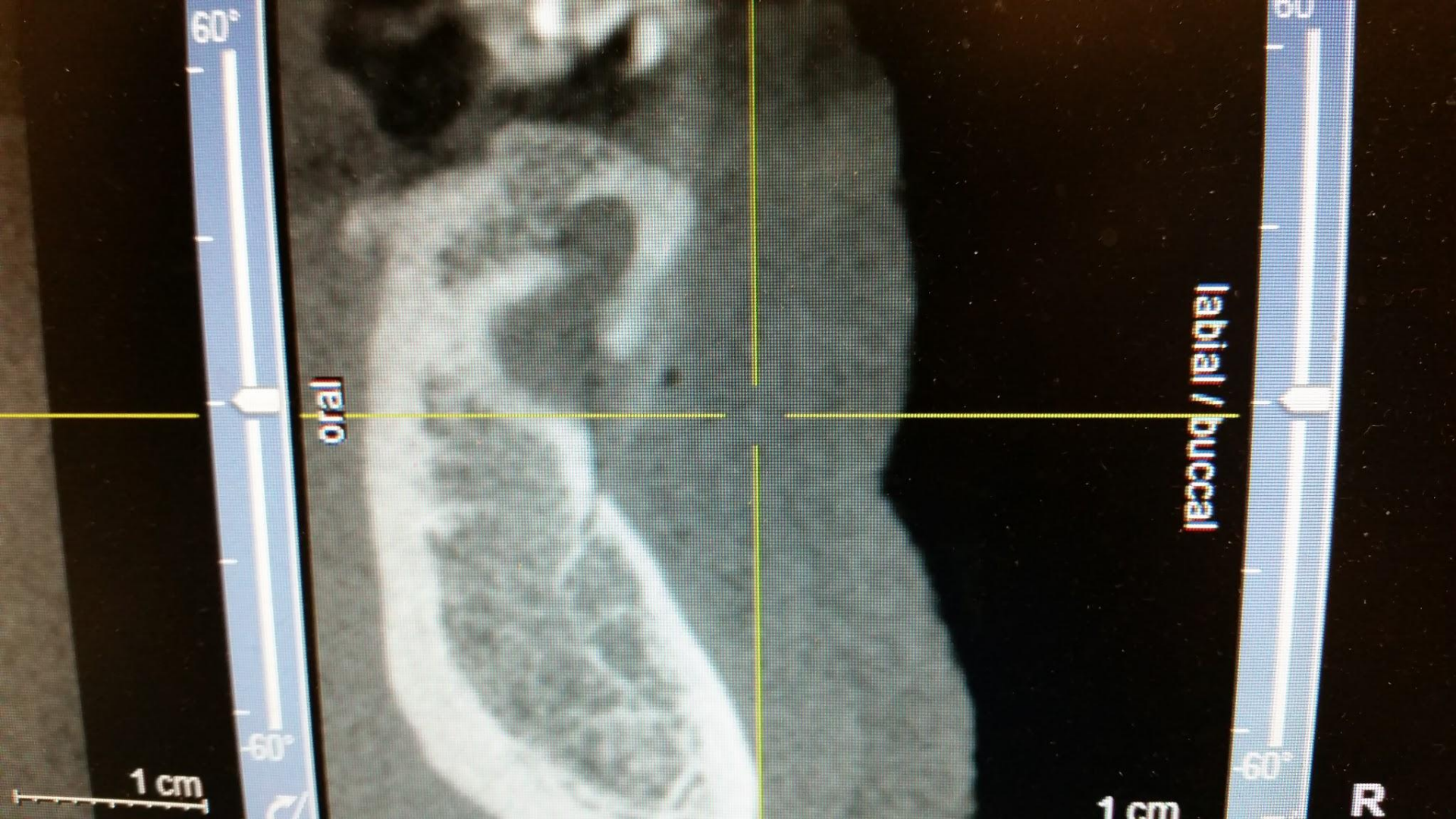oral

labial / buccal

60°

60°

1 cm



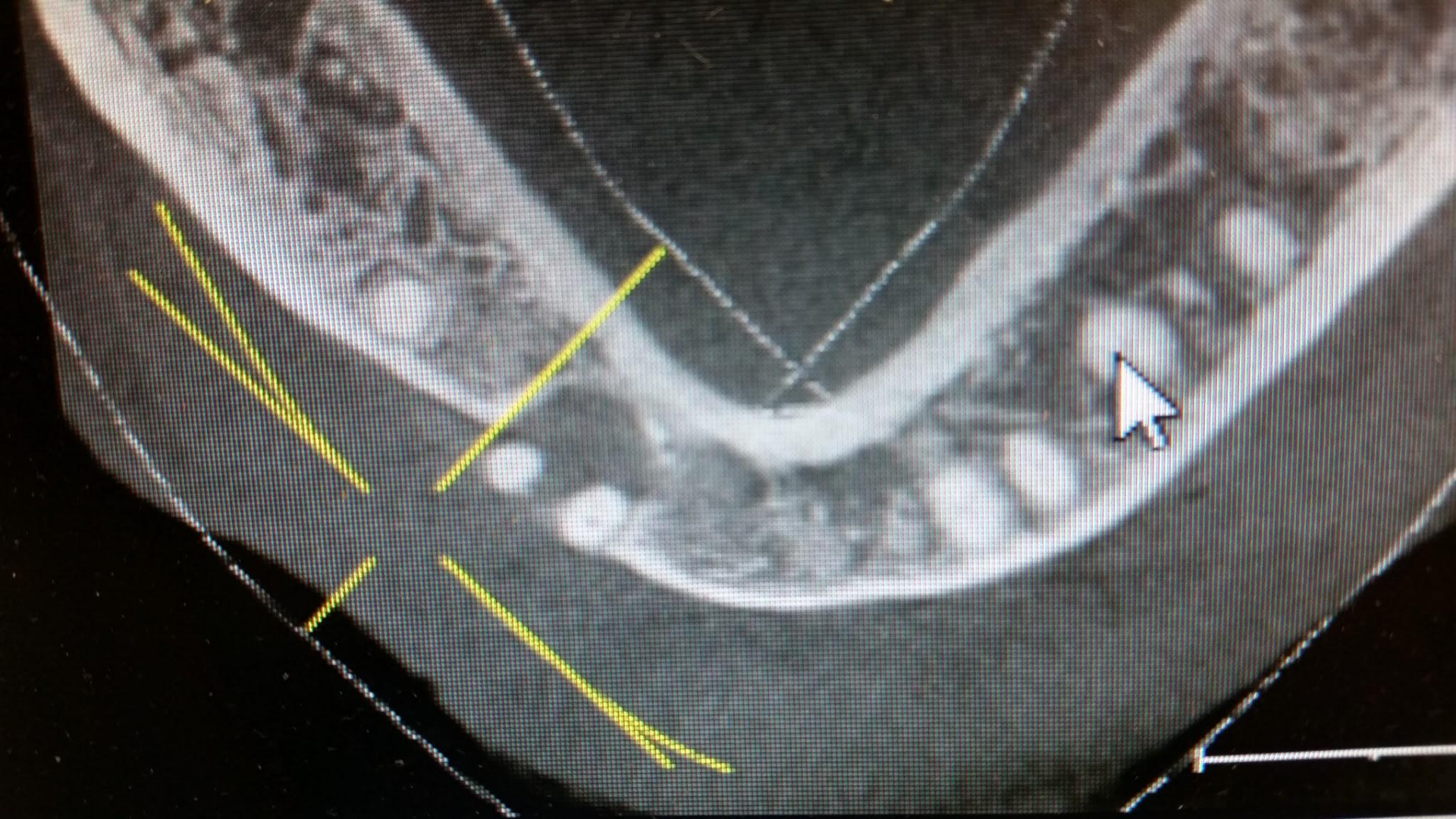
oral

labial / buccal

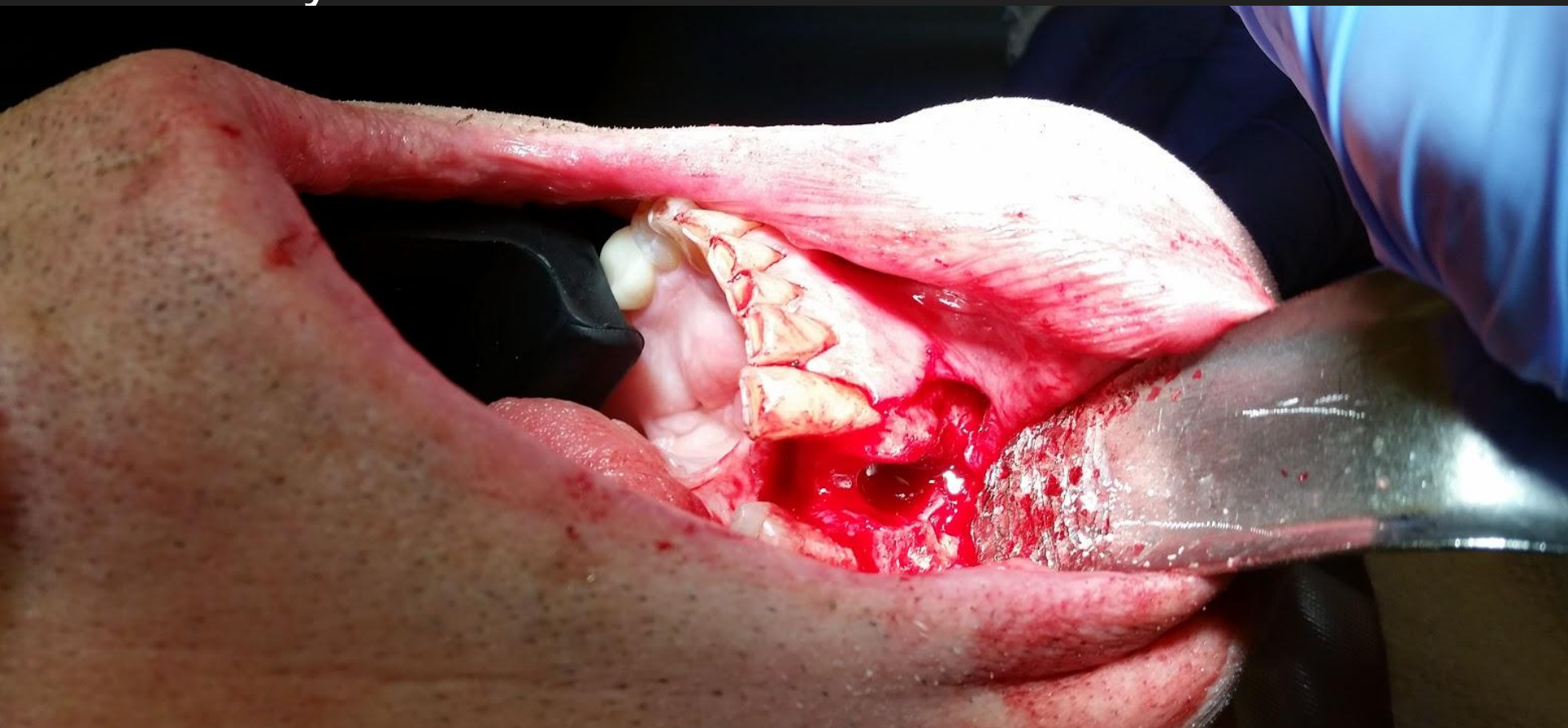1 cm

1 cm

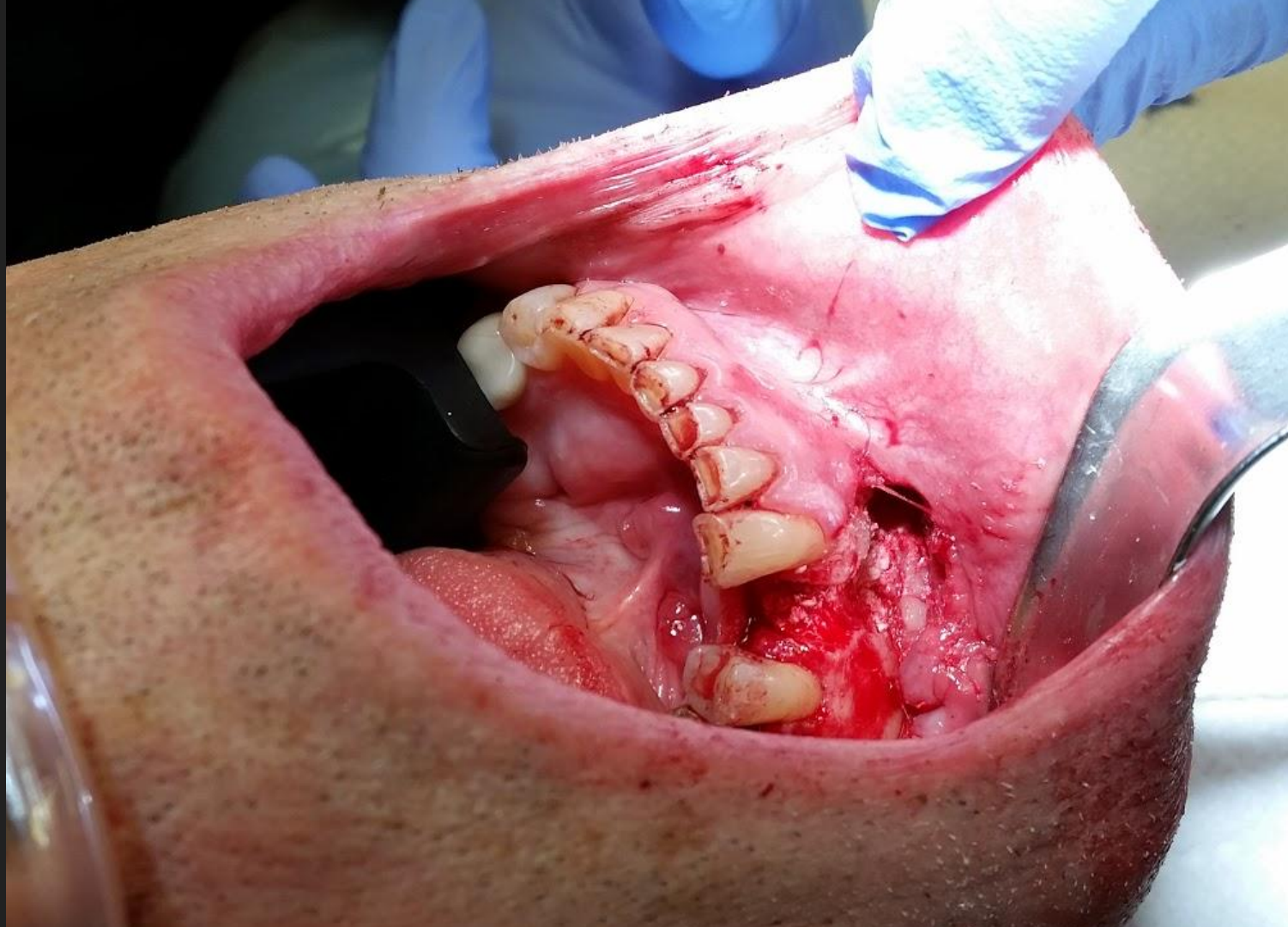R

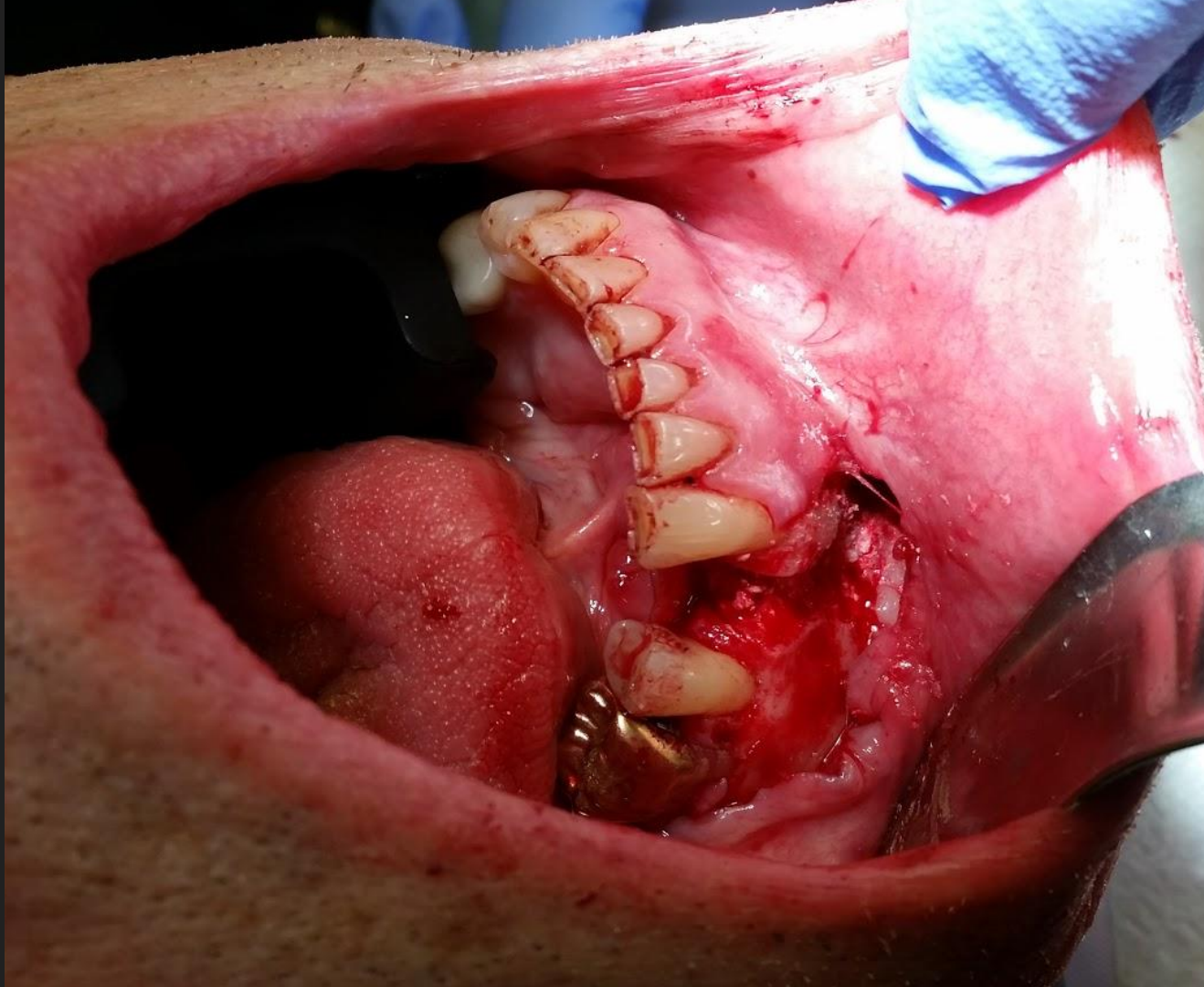

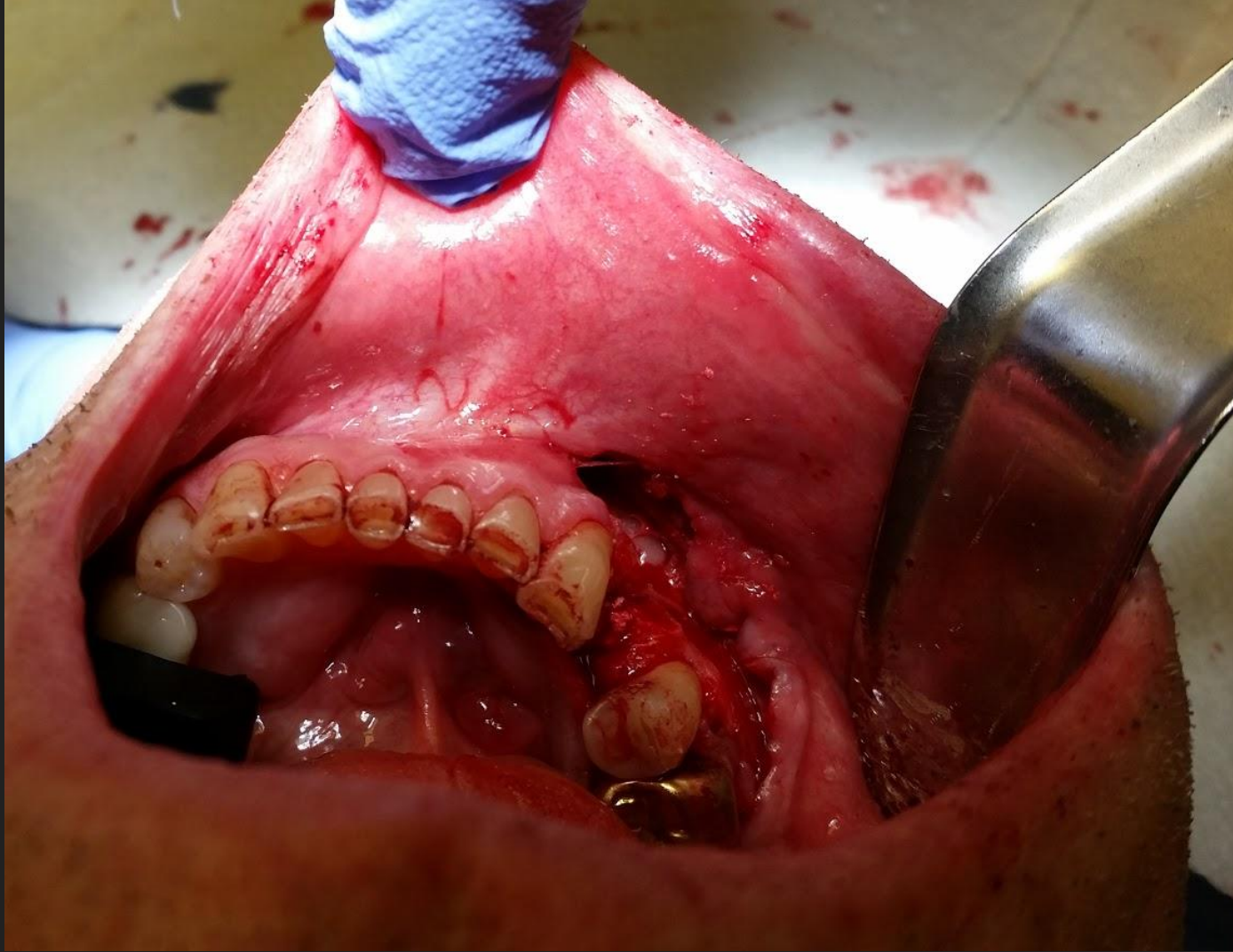28 and cyst removed











Text CANDY to 77948

www.dentistbraincandy.com