
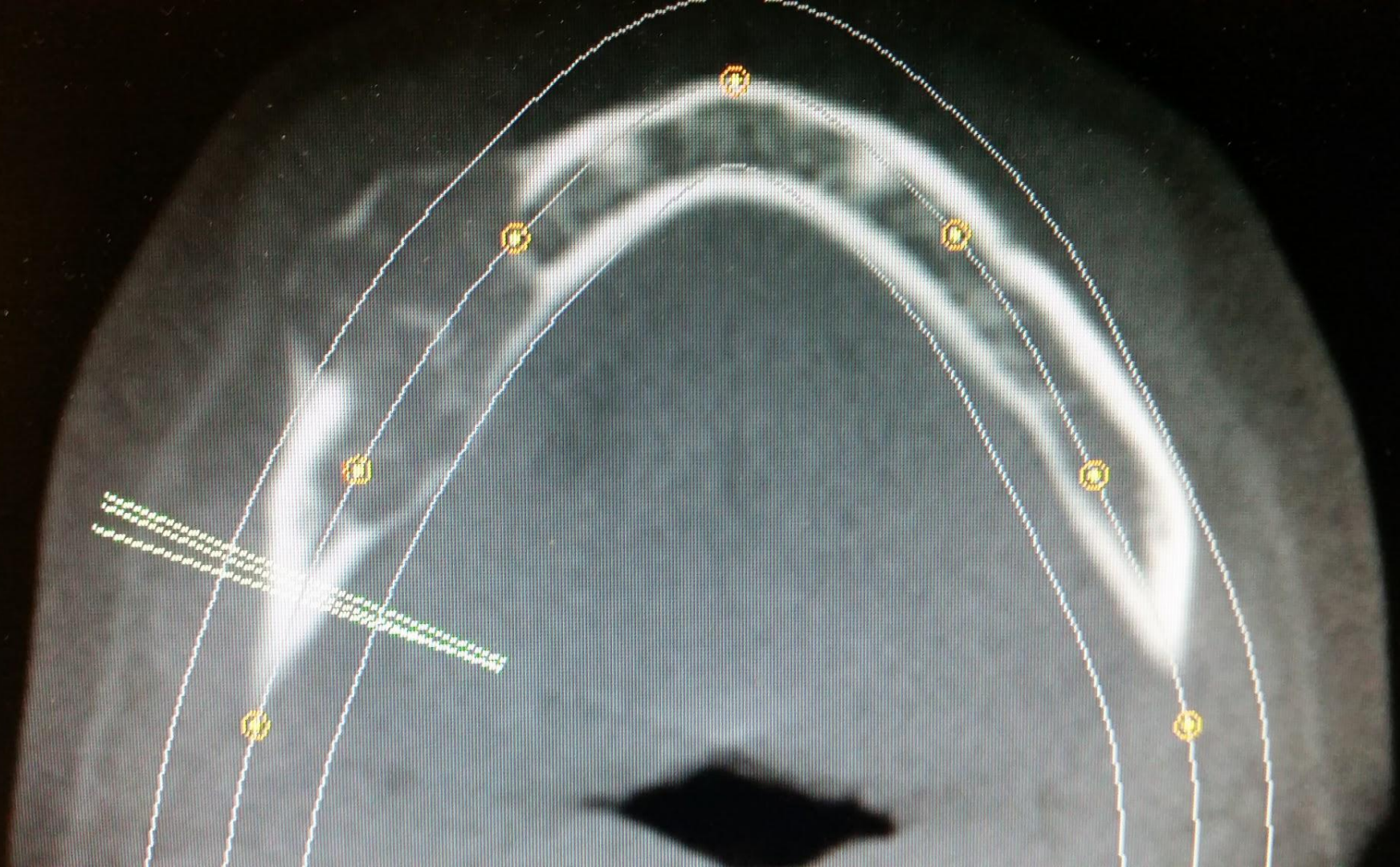
Central Giant Cell Granuloma of the Mandible

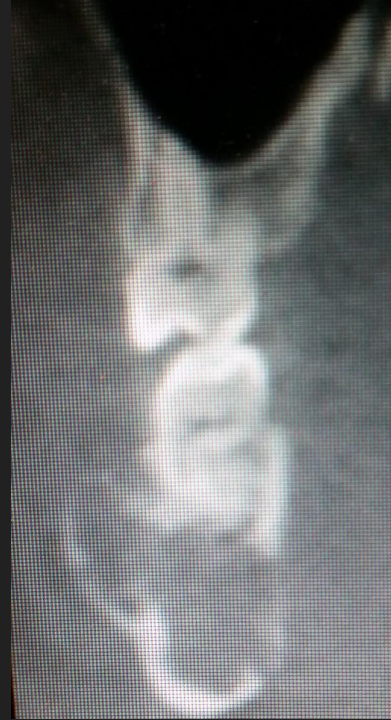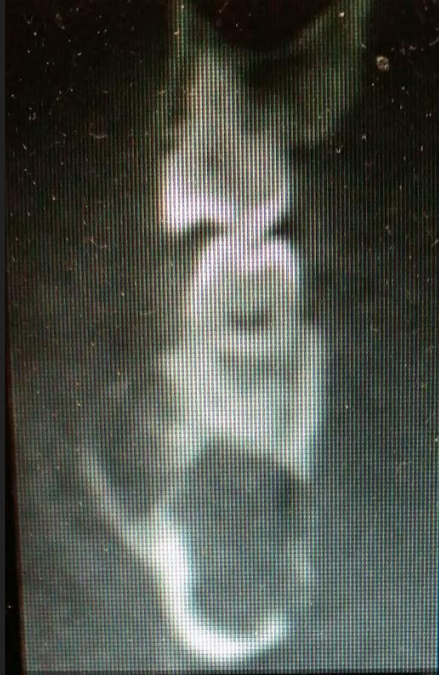Dr Bryan McLelland, DDS

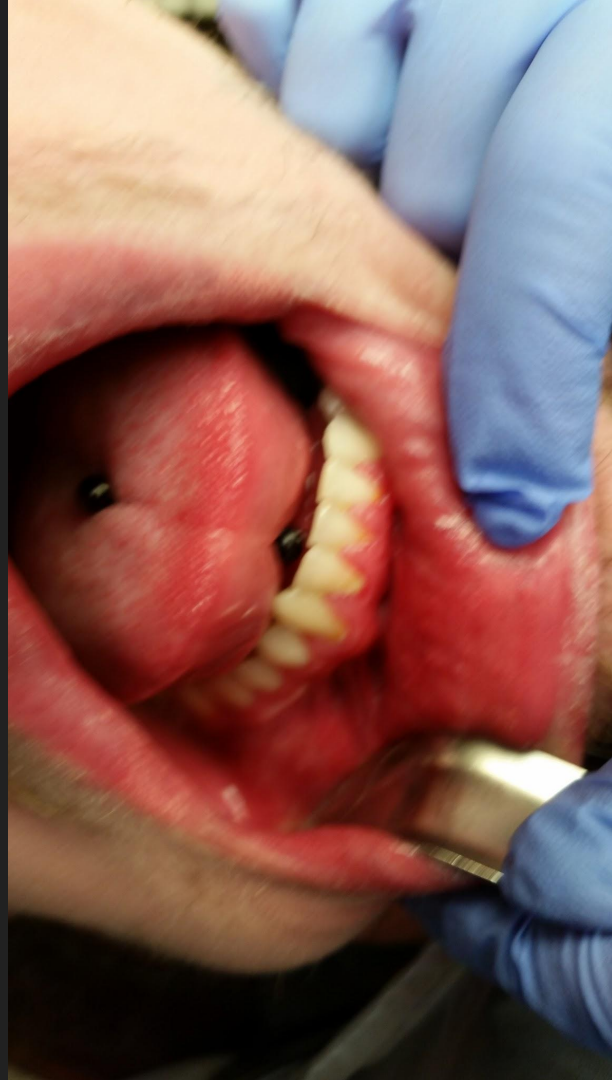

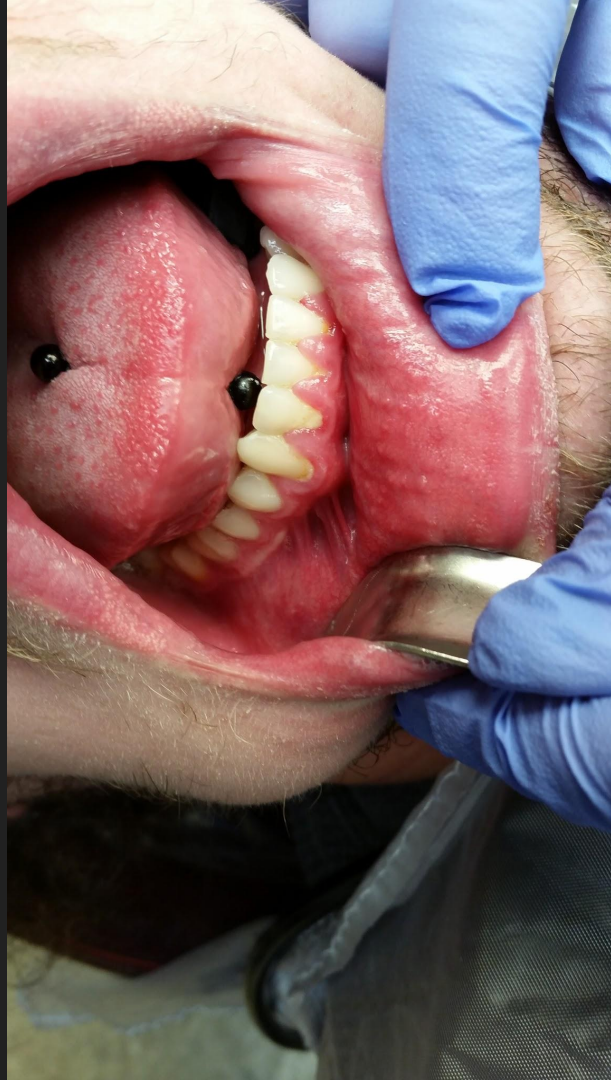ch, Ryan, P
3/1993

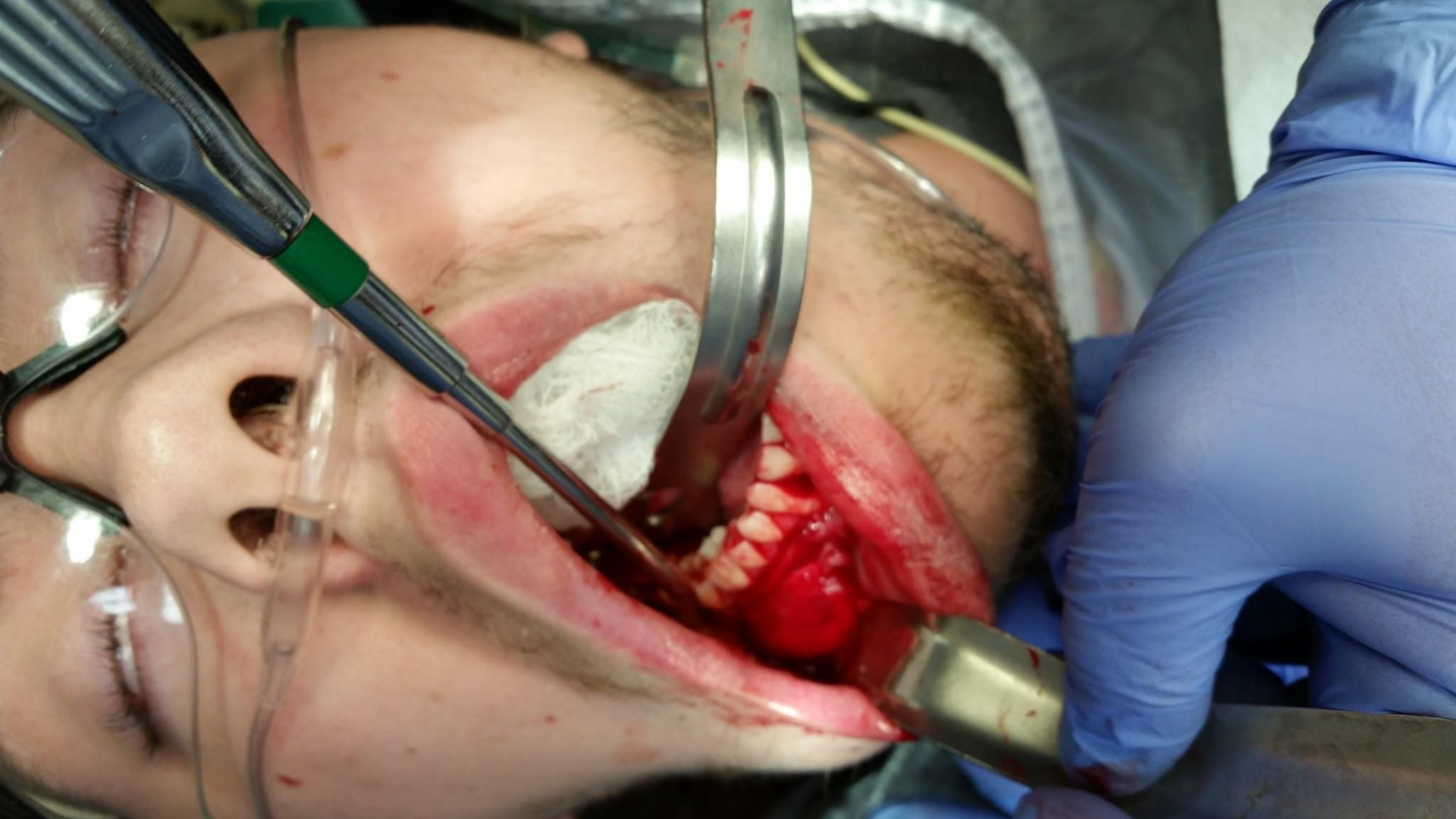

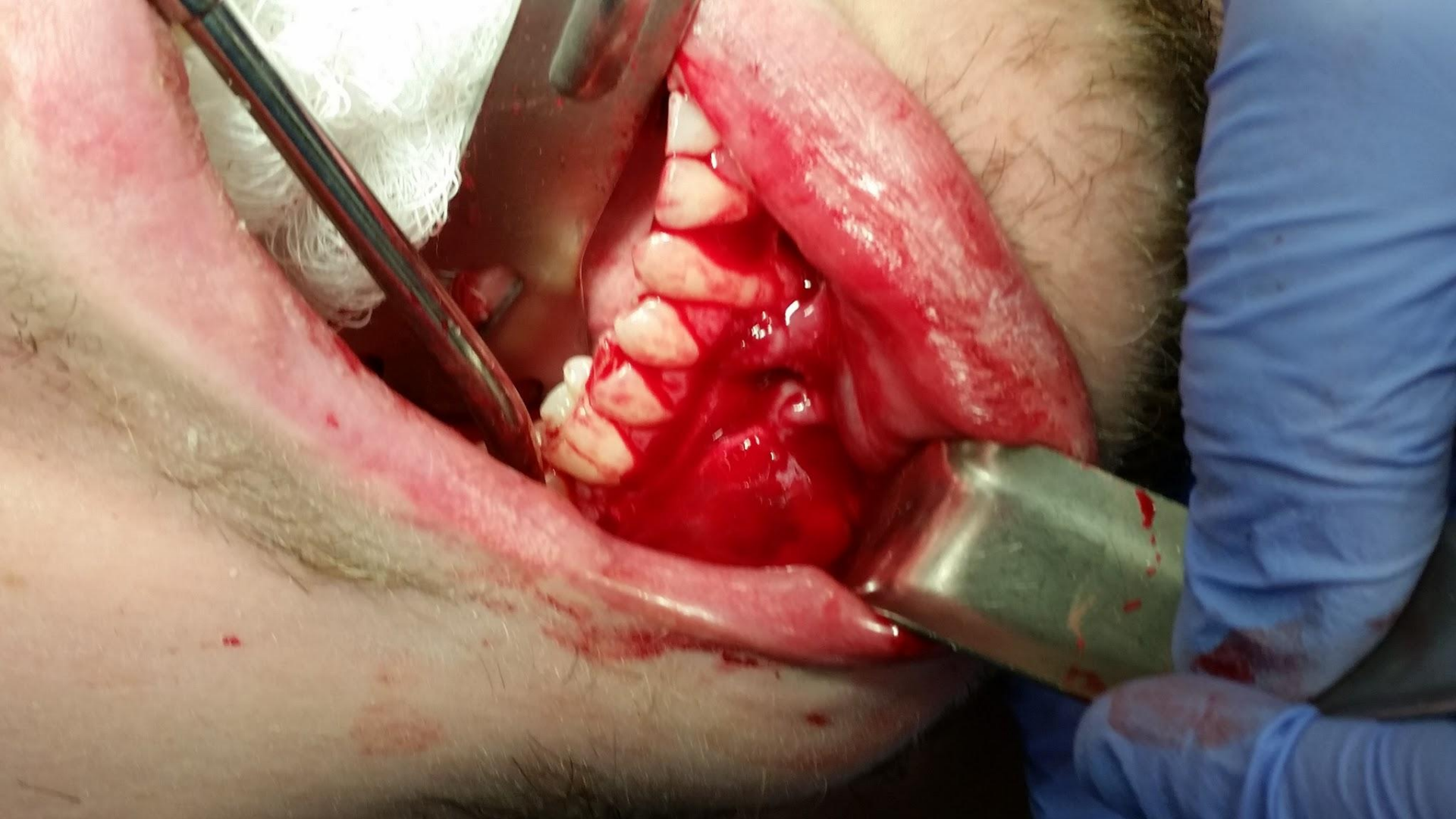Coronal cut through the tumor

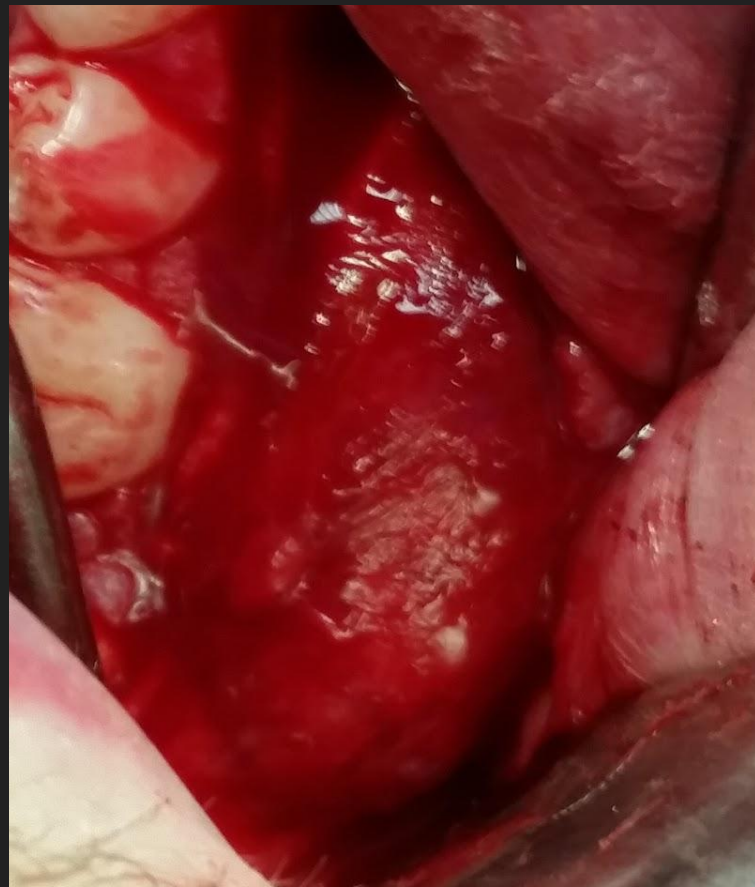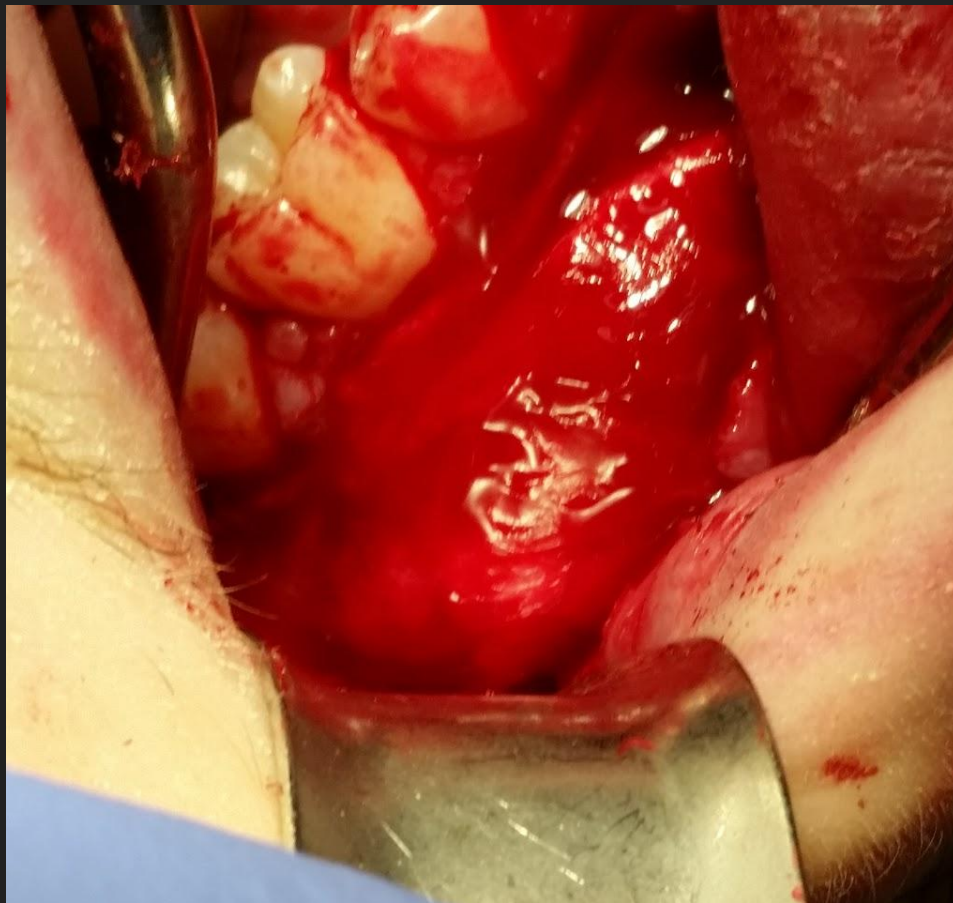



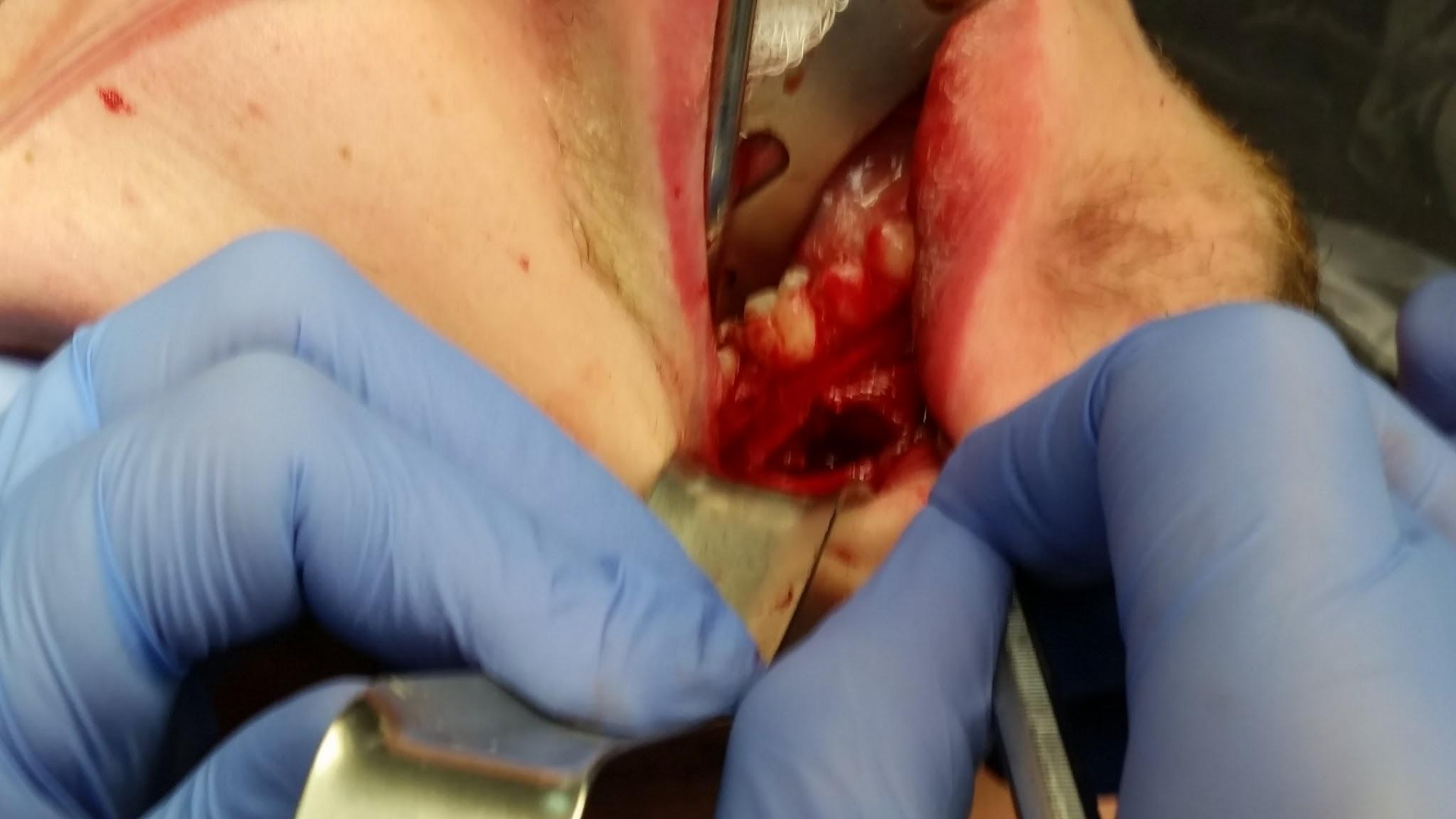


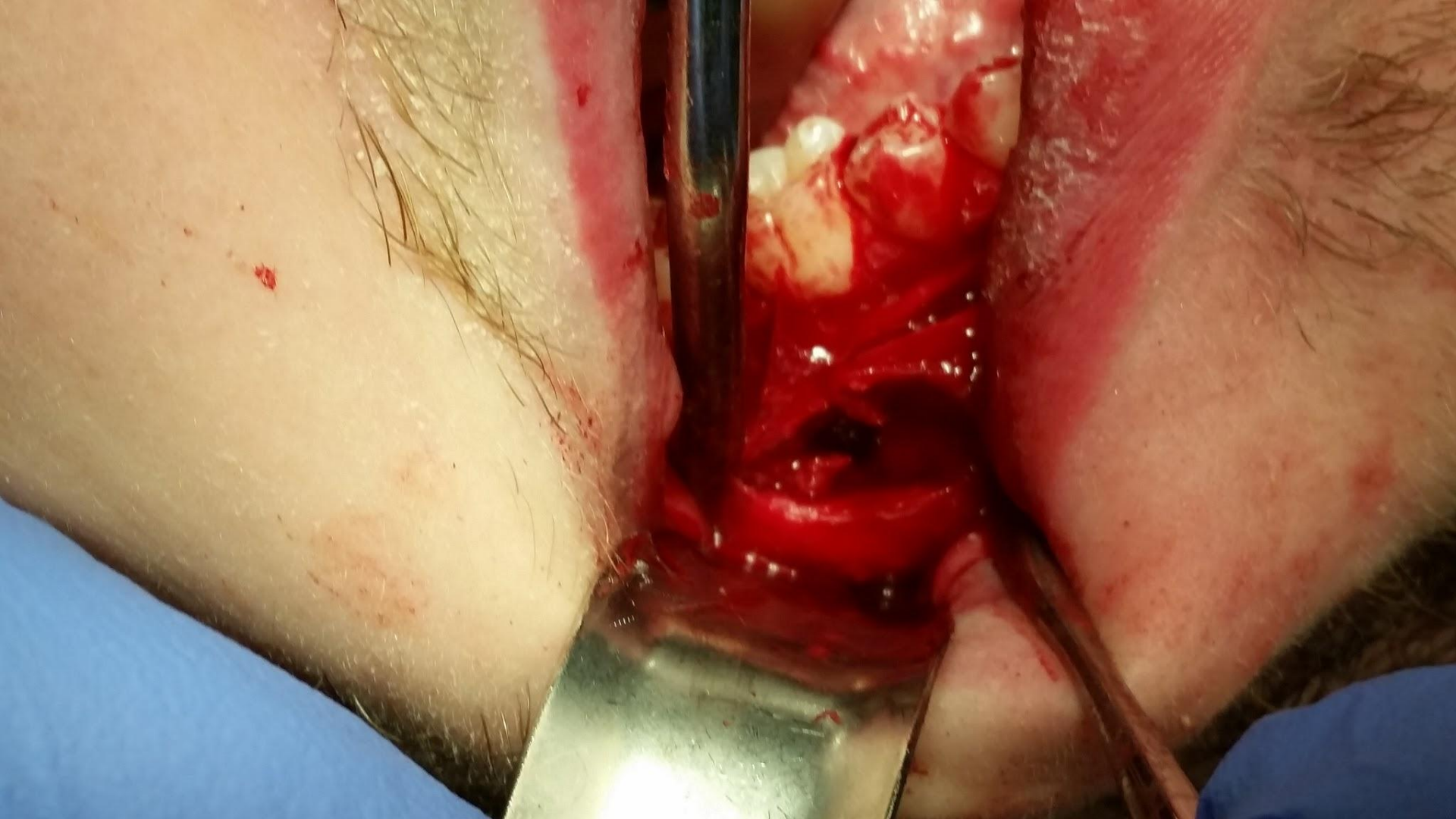

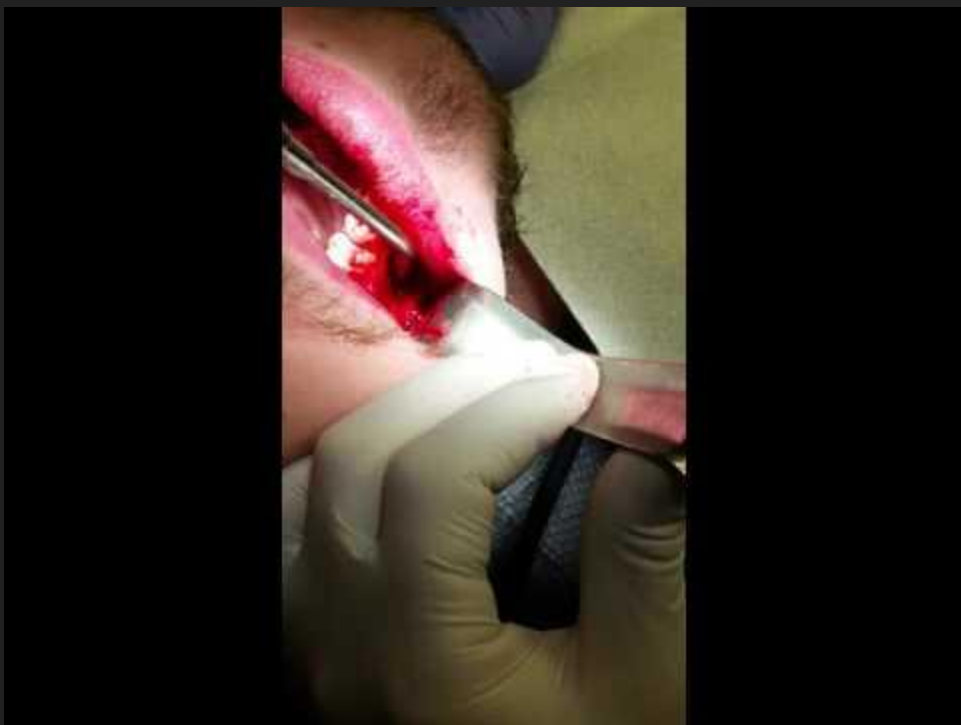












DENTIST BRAIN CANDY

www.dentistbraincandy.com

info@dentistbraincandy.com

Bryan McLelland,